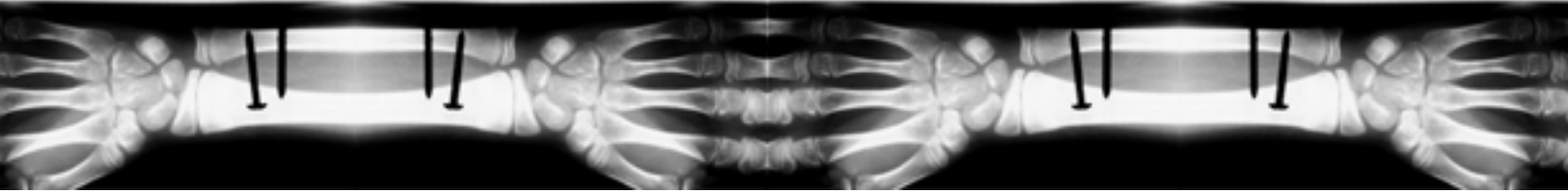


# Anatomy and Physiology- Semester Exam Review



## Chapter and topics covered

### 1- Orientation to Human body

Language of Anatomy - directional terms, regional terms, body planes

### 3- Cells: Living units

Cytoplasmic Organelles - mitochondria, ribosomes, e.r., Golgi apparatus, lysosome

Nucleus - genetic material

### 30 - Heredity

Vocabulary of genetics - genotype vs. phenotype, homozygous vs. heterozygous

dominant vs. recessive

Sex-linked inheritance

Karyotype

Human pedigree

Human Genome Project

### 4 - Tissue: Living fabric

Epithelium - simple epithelia (squamous, cubital, columnar), stratified epithelia, pseudostratified columnar

Connective tissue - bone (osteon, harversian system), cartilage (fibrocartilage, hyaline, adipose, areolar)

Muscle tissue - striated, smooth, cardiac

Nervous tissue - dendrites

### 5 - Integumentary system

Epidermis

Dermis

Appendages of skin - hair, nails, sweat glands, sebaceous glands

Functions of integumentary system - protection, temperature regulation, pressure sensation, excretion

Homeostatic imbalances of skin - burns, cancer

\*Shark dissection

### 6 -Bones and Bone tissue

Functions of bones

Classification of bones - long (epiphysis, diaphysis), short, irregular

Bone markings - tuberosity, crest, tubercle, trochanter, foramen, groove, ramus, condyle

Fractures - greenstick, compound, simple, impact

### 7 - Skeleton

Axial Skeleton

Skull - skull geography

cranium - frontal, parietal, occipital, temporal, sphenoid, ethmoid, sutures

facial - mandible, maxilla, zygomatic bones, nasal

Vertebral column

divisions (cervical, thoracic, lumbar, sacral, coccegeal)

curvatures (scoliosis, kyphosis, lordosis)

vertebral characteristics - identification of parts

\*Upright Posture lab

Appendicular skeleton

Shoulder girdle - clavicle, scapula

Upper limb - humerus, radius, ulna

Hand - carpals, metacarpals, phalanges

Pelvic Girdle - ilium, ischium, pelvic structures (ischial tuberosity, acetabulum, iliac crest, obturator foramen)

Lower limb - femur, tibia, fibula

Foot - tarsals, metatarsals, phalanges

### 8 - Joints

Classification of joints - structure, function

Fibrous (sutures), Cartilaginous (symphyses), Synovial (plane, hinge, pivot, condyloid, saddle, ball-and-socket)

Movement allowed by synovial joints

Selected synovial joints - knee, shoulder

Common joint injuries - dislocations, sprains

Inflammatory and degenerative conditions - arthritis